

The Ross Operation

Bedri Aldudak*, Cahide Tursun Aldudak*, Monika Lüdemann*

SUMMARY

Both congenital and acquired aortic valve defects represent an important group of diseases in pediatric patients. Since the defects –in form of stenosis, insufficiency or mixed- may finally cause a loss of ventricular function and mean a big load for the heart muscle, an interventional or surgical therapy is required. Although there are various alternatives of treatment, none of these is really satisfactory. The balloon valvuloplasty which is especially performed on patients with aortic stenosis does not seem to be a lasting solution. Also the replacement of homografts and mechanical valves in aortic position has not been as successful. Particularly problems like several re-operations, thromboembolic complications, frequent endocarditis, the need of anticoagulants and their risk of bleeding have forced us to search for new ways of therapy. In this respect the Ross procedure is the best option for pediatric patients.

Key Words: Aortic Valve Disease, Ross Operation

Ross Operasyonu

ÖZET

Gerek konjenital gerek akkiz olsun aort kapağı hastalıkları pediatrik yaş grubunda önemli bir yer tutar. Gerek darlık veya yetmezlik şeklinde gerekse de mikst tipte olsun hastalık sol ventrikülde fonksiyon kaybına yol açtığından nihayetinde girişimsel veya cerrahi bir girişimi gerekli kılmaktadır. Tedavi de birçok yaklaşım var olmakla birlikte hiçbiri tatmin edici değildir. Özellikle darlığı olan hastalarda uygulanan balon valvuloplasti kalıcı sonuçlar sağlamamaktadır. Aynı şekilde aortik pozisyona homografit veya mekanik kapak yerleştirilmesi de sonuçları itibarıyla başarılı sayılmaz. Özellikle tekrarlayan operasyon ihtiyacı, tromboembolik hadiseler, sık endokardit, devamlı oral antikoagülan kullanımı ve buna bağlı kanama riski tedavi için başka yollar aramaya zorlamaktadır. Bu açıdan Ross prosedürü pediatrik hastalar için uygun uygulamadır.

Anahtar Kelimeler: Aort Kapak Hastalığı, Ross Operasyonu

INTRODUCTION

Congenital and acquired aortic valve diseases represent an important group in pediatric cardiology. Hemodynamically relevant lesions – both stenosis and insufficiency - require an intervention in order to prevent any loss of left ventricular function or to improve functional status.

Interventional and surgical methods like balloon valvuloplasty and valvulotomy which are performed in patients with stenotic aortic disorders have not proved to be lasting solutions. An ideal valve replacement should be practicable with a low surgical risk - particularly in children - and guarantee a

* University of Giessen Pediatric Cardiology Department /Germany



normal valvular function. Besides it should not cause more than minimal restrictions in daily life and also should not require several reoperations. No ideal aortic valve prosthesis for children and young people is yet available (1). Nowadays, the Ross procedure is thought to be the best option of treatment in patients with aortic valve diseases. Especially in kids with congenital aortic valve diseases it is the preferential procedure (2 - 8). In comparison to alternatives like mechanical valve replacement or homografts placed in the aortic position, the Ross procedure seems to be more beneficial in most patients and with a low risk of mortality. There are several advantages of the Ross operation: The neo-aortic valve probably lasts a life-time and does not imply any additional work load for the heart muscle thanks to the low rate of subsequent aortic stenosis and insufficiency (9). This method is used successfully in many centers with a low mortality and morbidity (10). The rate of reoperation is lower compared to alternative procedures and the patients do not need any oral anticoagulation, because there is no increased risk for thromboembolic complications. There is a need for exchange of the homograft, though, after an average of 15 to 20 years, but the coronary arteries are spared. With the capabilities of catheter intervention (balloon valvuloplasty and angioplasty) some homograft exchanges can be delayed. Additionally, in pediatric patients the autograft has growth potential as the child or adolescent grows (11). Furthermore bioprosthetic valves develop degeneration and therefore the need of reoperation during the somatic development of the organism becomes very likely.

The first replacement of an aortic valve with a pulmonary autograft was performed by Sir Donald Ross in 1967. In the beginning cardio surgeons found this operation to be very complicated and technically difficult because of the coronary artery reimplantation technique. In recent years, Ross`method became more and more common because of the good results (12) due to altered surgical technique using total aortic root replacement.

The basic principle of the operation is to use the patient's own pulmonary valve for replacement of the diseased aortic valve. A homograft replaces the pulmonary valve (see fig. 1, 2, 3).

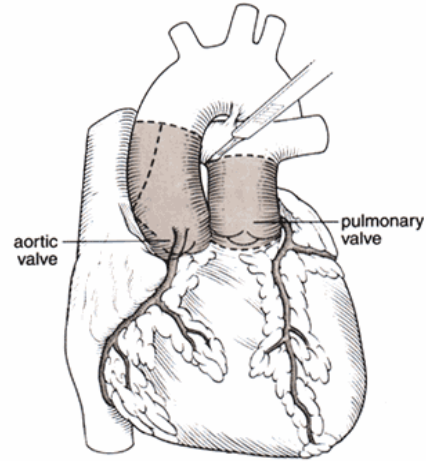


Figure 1. The pulmonary valve and a segment of the pulmonary artery are excised. This pulmonary segment will later be placed in the aortic position replacing the diseased aortic valve.

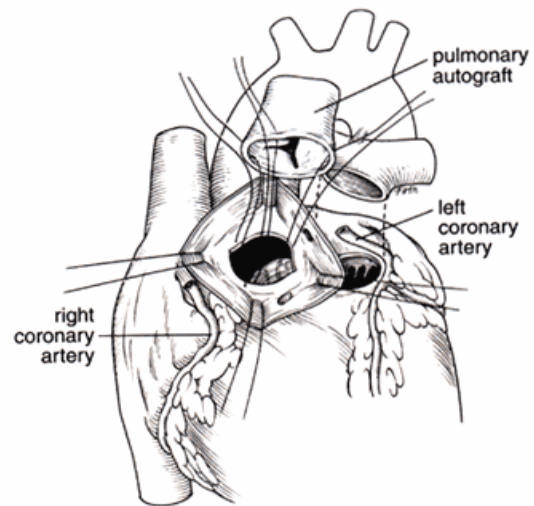


Figure 2. The diseased aortic valve and proximal tissue is removed, leaving the right and left coronary arteries with only a button of tissue



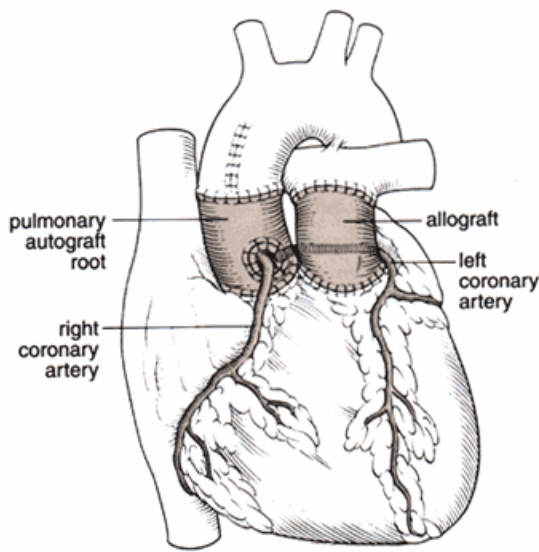


Figure 3. The pulmonary autograft is placed in the aortic position and the buttons of tissue on both the right and left coronary arteries are then sewn into that pulmonary segment and closed. A cadaveric pulmonary valve and artery homograft is then replaced in the pulmonary position to replace the excised pulmonary segment.

INDICATIONS

Today the diseased aortic valve is replaced by the patient's own pulmonary valve and a homograft is transplanted between the right ventricular outflow tract and the pulmonary artery.

The most important indications are:

Aortic Stenosis:

This disease represents about 5% of congenital heart defects and is generally tolerated well as long as pressure gradients between left ventricle and ascending aorta are low. Between 25 and 45 mmHg the patients do not need any intervention but they should be followed up regularly because during a period of 25 years surgical treatment will become necessary in 41% of cases in this group (13). For patients with severe aortic stenosis and a pressure gradient >80 mmHg a balloon dilatation or a surgical intervention is

recommended as otherwise they have to face risks like arrhythmia, left heart failure and sudden death.

The discussions about the patients with a pressure gradient between 50 and 79 mmHg have not come to an end yet. In any case a follow up and a limitation of physical activity are necessary. Exercise test may help reveal ischemia and / or arrhythmia in these patients.

In the last ten years the treatment of severe aortic stenosis with balloon valvuloplasty has largely replaced surgery. In unsuccessful valvuloplasty valvulotomy is the next treatment option. In cases failure of valvuloplasty or valvulotomy or in severe aortic insufficiency a valve replacement, preferably performed as a Ross procedure, becomes necessary. Unfortunately, about one third of the patients with valvuloplasty and valvulotomy develop restenoses over time necessitating valve replacement. In patients with subvalvular stenosis a Ross-Konno operation is performed which is a combination of the classic Ross procedure with subaortic outflow tract resection and plasty (4, 6, 7, 13-16).

Aortic Insufficiency:

In general this is a manifestation of a congenital anomaly of the aortic valve. Other causes include subaortic obstruction, interference of the aortic valve with a perimembranous outlet, especially subarterial VSD, and collagen tissue disorders. After some years of tolerance in most cases an aortic insufficiency leads to left ventricular dilatation and dysfunction resulting in heart failure and rhythm disturbances. The timing of a valve replacement depends upon the patients' symptoms. The intervention should be considered if the left ventricular dilatation is above two standart deviation, if the enddiastolic left ventricular dilatation is progressive, and if there is progressive left ventricular systolic dysfunction (ejection fraction <50%). ECG markers include ischemic ST - and T - wave abnormalities and dysrhythmia.

Both aortic insufficiency and stenosis or mixed lesions can be treated by the Ross



method with an acceptable mortality and morbidity rate in all age groups. The improvement of left ventricular diameter and function is remarkable (4, 15, 17 - 20).

Endocarditis in native and prosthetic aortic valve:

In these cases the Ross procedure is successfully combined with antibiotic therapy in the acute phase of heart failure and a lower mortality and morbidity rate compared to other valve replacement methods is described (10, 21).

Bicuspid aortic valve:

With a prevalence of 2% the bicuspid aortic valve is the most common congenital heart anomaly in the general population and can lead to aortic stenosis, insufficiency or a mixed defect. It is shown that in these patients a sclerosis of the valves begins in the second decade of life and calcifying stenosis develops with a peak in the fourth decade. The pressure gradient is thought to increase about 18-27 mmHg in each decade. Consequently we see the manifestation of symptoms mostly in adults (15, 20, 22). Because of marked poststenotic dilatation of the ascending aorta in this patient group Ross operation should be considered only if there is no significant mismatch between the diameters of the aorta and the pulmonary artery.

CONTRAINDICATIONS

Marfan Syndrome: This is the only situation which represents an absolute contraindication for the Ross operation.

Rheumatic valvular disorders and dysplastic dilated aortic roots are relative contraindications because of the postoperative dysfunction of the autografts (21).

ADVANTAGES

Growth potential: For pediatric patients this is the biggest advantage. The autograft can grow with the patient. This guarantees an optimal hemodynamic situation and makes several reoperations unnecessary (4, 19, 23).

Optimal haemodynamic performance: The pulmonary autograft produces an optimal

haemodynamic situation so that a regression of reversible ventricular damage is possible and the patients' health can improve rapidly (4, 8, 19, 23, 24).

Low mortality: In many countries the Ross method achieves a low early and late mortality rate of <5% in the hands of an experienced surgeon in any age group beginning in the neonatal period (4, 6, 21).

No need for prophylaxis with anticoagulants: Towards the artificial valves this is a huge advantage of the Ross method. This implies a lack of a risk of bleeding under oral anticoagulants – particularly for women who want to get pregnant (7, 19).

No degeneration: Immunologic reactions are limited by the use of autologous tissue, thereby reducing the rate of restenosis of the aortic valve. Immunologic reactions and calcification reduce the lifetime of homografts and cause reoperations, but studies show a longer reoperation-free period after Ross operations that after other aortic valve replacements. Therefore there is no further manipulation of the coronary arteries (25).

DRAWBACKS

Dysfunction of pulmonary homografts: The homografts placed between right ventricle and pulmonary artery show degenerative changes after some years. The younger the patient at the time of operation the more likely a reoperation during childhood or adolescence becomes. An ideal material for this connection should be researched (26, 27).

Aortic root dilatation and aortic valve insufficiency: If criteria like an aortic root diameter >4 cm or 0.21cm/m² body surface ratio are considered, aortic root dilatation is a problem in about 34% of the patients after a Ross operation. In the same study only 14% had a more than mild aortic valve insufficiency whereas this rate was much higher in patients with aortic root dilatation. Young age, preoperative aortic aneurysm and a pulmonary autograft replacement without an anulus and sinotubular junction seemed to be further risk factors (28-30).



Technical difficulties: Although the Ross procedure has numerous indications, it is considered to be a more complicated operation than an isolated valve replacement or a homograft placement in the aortic position (25). A one-valve pathology is treated by a two-valve operation. Homografts of appropriate size are not always available. Pulmonary homografts seem to have a better outcome than aortic homografts for unknown reasons.

CONCLUSIONS

We do not have any ideal method in the treatment of aortic valve diseases. Each method has its own disadvantages.

The mechanical valves cannot be used in all age groups. They may cause thromboembolic events so that patients have to take anticoagulants for the rest of their lives.

Homograft replacement in the aortic position also has problems: The homograft material is not long lasting and available at any time or in any size, it tends to degeneration and lacks growth potential.

In comparison to these methods the Ross procedure can be used in all ages in many centers of the world with a low mortality and a low rate of reoperation. It is superior because of the growth potential of the autografts, ideal haemodynamic possibilities and rare thromboembolic events. The patients are not dependent on anticoagulants which is an important aspect especially for women in the reproductive age. For all these reasons the Ross procedure is preferred in the treatment of aortic valve diseases especially in pediatric patients (2, 7, 31-35). The problem of necessary redos of the homografts has not been solved, but the advantage of only one surgery in a life-time on the coronary arteries outweighs this disadvantage. The choice of homograft / xenograft material and its pre-implantation preparation (cell extraction etc.) are matters of research studies at present and will possibly offer an improvement in the future.

Nowadays the development of interventional cardiology with stents including stent valves and their use in the treatment of

pulmonary stenosis and insufficiency point out that these alternatives may replace the Ross procedure as the routine and primary option in the therapy of aortic valve disorders in the future.

REFERENCES

1. Raja SG, Pozzi M. Ross Operation in children and young adults: the alder Hay case series, *BMC Cardiovascular Disorders*, 2004; 4:3
2. Hartyanszky I, Kollar A, Szatmari A, et al. Aortic Root Replacement with Pulmonary Autograft (Ross procedure) in Children. Early results *Orv Hetil*. 2002 21;143(29)1745-8
3. Hartyanszky I, Kollar A, Szatmari A, Ablonczy L. Successful management of early aortic root abscess with aortic homograft implantation in children after Ross operation. *Magy seb*, 2002; 55:100-2.
4. Al Halees Z, Pieters F, Qadoura F, et al. The Ross procedure is the procedure of choice for congenital aortic valve disease. *J Thorac Cardiovasc Surg*, 2002; 123:437-41.
5. Brown JW, Rumetov M, Vijay P, Bills RG, Turrentinne MW. Clinical outcomes and indicators of normalization of left ventricular dimensions after Ross procedure in children. *Semin Thorac Cardiovasc Surg*, 2001;13:28-34.
6. Sankar NM, Goel P, Agarwal H, Srinivas S, Cherian KM. Ross procedure in an infant. *Indian Heart J*, 2001; 53:346-7.
7. Spray TL. Technique of pulmonary autograft valve replacement in children (the Ross procedure). *Semin thorac cardiovasc Surg pediatr card surg Annu*. 1998;1:165-178
8. Xie GY, B hakta D, Smith MD. Echocardiographic follow-up of the Ross procedure in older versus younger patients. *Am Heart J*, 142:331-35.
9. Sana Hezchirurgische Klinik Stuttgart GmbH, <http://www.aspr.de/shs/herzmedizin/ros-op.php3>
10. Birk E, sharoni E, Dagan O, et al. The Ross procedure as the surgical treatment of active aortic valve endocarditis. *J Valve Dis*, 2004; 13:73-7.



11. Ohye RG, Bove EL. Current Topics in Congenital Heart surgery. In: Allen HD, Gutgessel HP, Clark EB, Driscoll DJ. Heart disease in infants, children, and adolescents. 6th ed. Philadelphia, Williams&Wilkins, 2001: 382-394.
12. Concha M, Legarra JJ, Casares C, et al. Aortic valve replacement with pulmonary autograft. (The ross procedure)in adult and pediatric patients. Rev Esp Cardiol, 2000; 53 suppl 1:28-38.
13. Freed MD. Aortic stenosis. Heart disease in infants, children, and adolescents 6th ed. Philadelphia, Williams&Wilkins 2001:971-982.
14. Brown JW, Ruzmetov M, Vijay P, Rodefeld MD, Turentine MW. Surgery for aortic stenosis in children: a 40 year experience. Ann Thorac Surg, 2003; 76:1398-411.
15. Oswald JD, Dewan SJ, Mueller MC, Nelson S. Highlights of a ten year experience with the ross procedure. Ann Thorac Surg, 2001; 71:332-5.
16. Lambert V, Obreja D, Losay J, et al. Long- term results after valvulotomy for congenital valvar stenosis in children. Cardiol Young, 2000; 10:590-96.
17. Kollar A, Hartyanzky I, Kadar K, Oprea V, Krnyei L, Szatmari A. Orv Hetil. 2002; 28;143(30)1779-81.
18. Marino BS, Bridges ND, Paridom SM. Aortic insufficiency: Indications for surgery in children. Semin Thorac Cardiovasc Surg pediatric card surg Annu. 1998;1:147-156.
19. Laudito A, Brook MM, Suleman S, et al. J Thorac Cardiovasc Surg, 2001; 122:147-53
20. Daniels CJ, Allen HD, Fontana ME. Adolescent and young adult cardiology. Heart disease in infants, children, and adolescents. 6th edn. Philadelphia, Williams&Wilkins 2001: 582-599.
21. Morita K, Kurosawa H. Indications for and clinical outcome of the ross procedure: A review. Nippon Geka Gakkai Zasshi, 2001; 102:330-6.
22. Santini F, Luciani GB, Barozzi L, et al. The Ross procedure for replacement of the bicuspid aortic valve:midterm results from 55 consecutive cases. J Heart Valve Dis, 2002; 11:226-30.
23. Pessoto R, Wells WJ, Baker CJ, Luna C, Starnes VA. Midterm results of the ross procedure. Ann Thorac Surg, 2001; 71:336-9.
24. Legarra JJ, Concha M, Casares J, et al. Behavior of the pulmonary autograft in systemic circulation after the ross procedure. Heart Surg Forum, 2001; 4:128-34.
25. Turrentinne MW, Ruzmetov M, Vijay P, Bills RG, Brown JW. Biological versus mechanical aortic valve replacement in children. Ann Thorac Surg, 2001; 71:356-60.
26. Kanter KR, Fyfe DA, Mahle WT, Forbes JM, Kirshbom PM. Results with the freestyle porcine aortic root for right ventricular outflow tract reconstruction in children. Ann Thorac Surg, 2003; 76:1889-94.
27. Allen BS, El-Zain C, Cuneo B, et al. Pericardial tissue valves and Gore-texconduits as an alternative for right ventricular outflow tract replacement in children. Ann Thorac Surg, 2002; 74:771-7.
28. Roux PM, Saad N. Modified Ross procedure for dysplastic ascending aorta. Ann Thorac Surg, 2003; 76:1754-56.
29. Luciani GB, Casali G, Favaro A, et al. Fate of the aortic root late after Ross operation. Circulation, 2003; 9;108 suppl 1:II61-7.
30. Ishizaka T, Devaney EJ, Ramsburgh SR, et al. Valv sparing aortic root replacement for dilatation of the pulmonary autograft and aortic regurgitation after the Ross procedure. Ann Thorac Surg, 75:1518-22.
31. Lupinetti FM, Duncan BW, Lewin M, Dyamenahalli U, Rosenthal GL. Comparison of autograft and allograft aortic valve replacement in children. J Thorac Cardiovasc Surg, 2003;126:240-6.
32. Mitchel BM, Strasburger JF, Hubbard JE, Wessel HU. Serial exercise performance in children with surgically corrected congenital aortic stenosis. Pediatr Cardiol, 2003;24:319-24.
33. Takkenberg JJ, Dossche KM, Hazekamp MG, et al. Dutch Ross study Group. Report of the Dutch experience with the ross procedure in 343 patients. Eur J Cardiothrac

Cilt:31, Sayı:3, (78-84)

Surg, 2002;22:70-7.

34. Da Costa FD, da Costa MB, da Costa IA, Poffo R, Sardeto EA, Matte E. Clinical experience with Heart valve Homograft in Brazil. *Artif Organs*, 2001;25:895-900.

35. Bohm JO, Botha JA, Hemmer W, et al. The Ross operation as combined procedure and in complicated cases—is there an increased risk? *Torac Cardiovasc Surg*, 2001;49:300-5.

