

Biventricular Myocardial Noncompaction

Onder Ozturk*, Unal Ozturk**, Nizamettin Toprak***

SUMMARY

The isolated noncompacted ventricular myocardium (NCVM), characterized by excessively prominent trabecular meshwork and deep intertrabecular recesses, is seen in the early period of embryogenesis. Clinical manifestations of NCVM are symptoms associated with depressed left ventricular systolic function, with ventricular arrhythmias, and with systemic embolization. Characteristics on echocardiography have been defined as absent coexisting cardiac abnormalities, non-compacted trabecular endocardium with deep endomyocardial spaces, predominant localisation of the trabeculation to mid-lateral, apical and mid-inferior segments, and a colour Doppler evidence of deep perfused intertrabecular recesses. We describe a case of isolated noncompaction of the left and right ventricular myocardium in a 17-year-old man who presented initially with palpitation and syncope.

Key Words: Myocardial Noncompaction, Echocardiography, Syncope.

Her İki Ventrikülü Tutan Miyokardiyal Non-Compaction

ÖZET

İzole ventriküler miyokardiyal non-compaction, embriyogenenin erken döneminde görülen aşırı belirgin trabeküler yapı ve trabeküller arası derin girintiler ile karakterizedir. İzole ventriküler miyokardiyal non compactionun klinik bulguları; bozulmuş sol ventrikül sistolik fonksiyonu, ventriküler aritmi ve sistemik embolidir. Ekokardiyografik özellikleri, birlikte başka bir kardiyak anomali olmaksızın, derin endomiyokardiyal boşluklar ile birlikte trabeküler endokard süngerimsidir. Trabekülasyon belirgin olarak mid-lateral, apikal ve mid-inferiyör segmentlerde lokalizedir. Trabeküller arası girintilerde renkli doppler ile kan akımı saptanır. Bu çalışmada, 17 yaşında çarpıntı ve bayılma şikayeti ile gelen erkek hastada, sol ve sağ ventriküler miyokardiyal non-compaction olgusu sunulmuştur.

Anahtar Kelimeler: Miyokardiyal Non-Compaction, Ekokardiyografi, Senkop.

INTRODUCTION

The isolated noncompacted ventricular myocardium, characterized by excessively prominent trabecular meshwork and deep intertrabecular recesses, is seen in the early period of embryogenesis. It occurs in the absence of other structural heart diseases and is thought to be due to an arrest of myocardial morphogenesis. This rare disorder is usually

seen in the left ventricle. However, to our knowledge there has not been reported isolated noncompaction of the left and right ventricular myocardium. We describe a case of isolated noncompaction of the left and right ventricular myocardium in a 17-year-old man who presented initially with palpitation and syncope.

* Guneydogu Hospital, Department of Cardiology, Diyarbakir

** Dicle University School of Medicine, Department of Public Health, Diyarbakir

*** Dicle University School of Medicine, Department of Cardiology, Diyarbakir



CASE REPORT

A 17-year-old man consulted our hospital for palpitation and syncope 2 years ago. Syncope and palpitation have occurred five times over the last 2 years. Physical examination was normal. His pulse rate was 50 bpm and blood pressure 110/80 mm-Hg. Electrocardiography demonstrated sinusual bradycardia. Chest X-ray was normal.

Admission transthoracic echocardiography revealed left ventricle with moderately impaired systolic function (Fig. 1). Left ventricular anterior, lateral apical, inferior walls and interventricular septum were hypokinetic. Multiple prominent muscular trabeculations were present in the left ventricle most evident at the apical, anterior septum and the posterolateral wall. Deep intertrabecular spaces were evident on the two-dimensional echo (Fig 2). These findings are pathognomonic for ventricular non-compaction. Also right ventricular free wall mid and apical were hypokinetic. Multiple prominent muscular trabeculations were present in the right ventricle most evident at the apical and the right ventricular mid free wall (Fig 3).

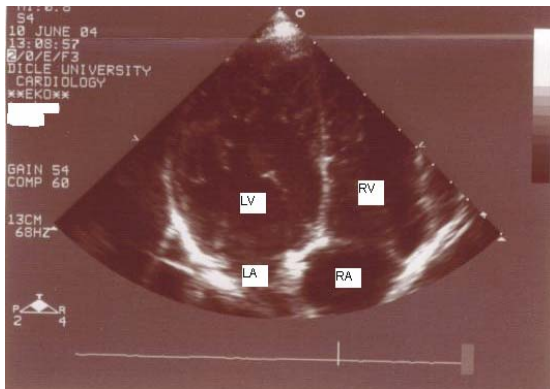


Figure 1. Two-dimensional echocardiography apical four-chamber view of left ventricle. Excessive and prominent trabeculation of the left ventricle is visible.

LV: Left Ventricle, LA: Left Atrium, RV: Right Ventricle, RA: Right Atrium.

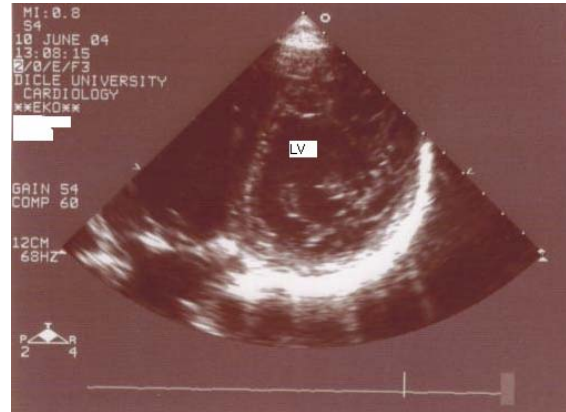

Figure 2. Two-dimensional echocardiography parasternal short-axis view of left ventricle. Excessive and prominent trabeculation of the left ventricle is visible.

LV: Left Ventricle.

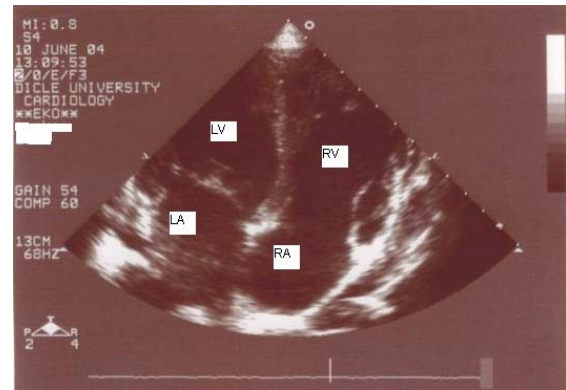


Figure 3. Two-dimensional echocardiography apical four-chamber view of right ventricle. Excessive and prominent trabeculation of the right ventricle is visible.

LV : Left Ventricle, LA : Left Atrium, RV : Right Ventricle, RA : Right Atrium.

Tilt table test showed a vasovagal syncope. Holter ECG was normal. Electrophysiological study was normal. The patient was started on silazapril and aspirin and was discharged. At present, the patient is being treated medically, as an outpatient, for congestive heart failure. His condition has remained relatively stable over the last year (New York Heart Association class I-II).

DISCUSSION

During normal embryogenesis, the loosely interwoven meshwork of myocardial fibers becomes more compact towards the epicardial surface and condenses to a compact wall. Noncompaction of ventricular myocardium (NCVM), is believed to be the result of an arrest in endocardial morphogenesis. This process resulting in a thickened left ventricular wall with deep intertrabecular recesses (1). Recent studies on genetic linkage analysis has revealed that mutations in the gene G4.5 on the Xq28 chromosomal region are responsible for NCVM and that this disorder is allelic with Barth syndrome (X-linked disorder associated with dilated cardiomyopathy, skeletal myopathy, neutropenia and abnormal mitochondria) (2,3). Clinical manifestations of NCVM are symptoms associated with depressed left ventricular systolic function, with ventricular arrhythmias, and with systemic embolization. The mechanism of ventricular arrhythmia is also unclear, but the similarity of noncompacted left ventricular myocardium to arrhythmogenic right ventricular dysplasia has been pointed out. Left ventricular architecture, as well as decreased contractility, predispose these patients to systemic embolization (4). This rare disorder is usually seen in the left ventricle. However, to our knowledge there has not been reported isolated noncompaction of the left and right ventricular myocardium in adolescence. Our patient had depressed both left and right ventricular function, and was symptomatic for palpitation and syncope.

Many diagnostic modalities have been evaluated for diagnosis of NCVM. CT and MRI can provide high-resolution imaging of non-compacted myocardium and may indicate a disturbed microcirculation due to fibrosis and thrombus formation (5).

Characteristics on echocardiography have been defined as absent coexisting cardiac abnormalities, non-compacted trabecular endocardium with deep endomyocardial spaces, predominant localisation of the trabeculation to mid-lateral, apical and mid-inferior segments, and a colour Doppler evidence of deep perfused intertrabecular

recesses (6). As physicians are becoming more aware of this rare disorder, previously missed patients may be diagnosed, and the true prevalence and natural course of NCVM will be better elucidated and understood in the future.

In conclusion, isolated noncompacted myocardium is usually seen in the left ventricle. However, to our knowledge this case is the first report isolated noncompaction of the left and right ventricular myocardium.

REFERENCES

1. Laat LE, Galema TW, Krenning BJ, Roelandt JR. Diagnosis of non-compaction cardiomyopathy with contrast echocardiography. *Int J Card* 2004; 94: 127-128.
2. Dusek J, Ostadal B, Duskova M. Postnatal persistence of spongy myocardium with embryonic blood supply. *Arch Pathol* 1975; 99: 312-317.
3. Ichida F, Hamamichi Y, Miyawaki T, et al. Clinical features of isolated noncompaction of the ventricular myocardium: long-term clinical course, hemodynamic properties, and genetic background. *J Am Coll Cardiol* 1999; 34: 233-240.
4. Shah CP, Nagi KS, Thakur RK, Boughner DR, Xie B. Spongy Left Ventricular Myocardium in an Adult. *Tex Heart Inst J* 1998; 25: 150-151.
5. Hamamichi Y, Ichida F, Hashimoto I, et al. Isolated noncompaction of the ventricular myocardium: ultrafast computed tomography and magnetic resonance imaging. *Int J card Imaging* 2001; 17: 305-314.
6. Jenni R, Oechslin E, Schneider J, Attenhofer Jost C, Kaufmann PA. Echocardiographic and pathoanatomical characteristics of isolated left ventricular non-compaction: a step towards classification as a distinct cardiomyopathy. *Heart* 2001; 86:666-671.

Address for Correspondence and Reprints

Onder OZTURK
Guneydogu Hospital, Department of Cardiology,
Diyarbakir
E-mail: oozturk@dicle.edu.tr

